



Effectiveness and Compatibility of MUCOKEHL

Observation on its Use for Ulcus Cruris in Clinical Practice

by M. Al-Haj, MD

As is commonly known, *Ulcus cruris* indicates an ulcer in the lower leg due to local disturbances in the venous and arterial circulation. For the therapy of these wide spread diseases, the SANUM preparations MUCOKEHL 5X for injection and MUCOKEHL 3X ointment were examined in patients regarding effectiveness and compatibility. Both SANUM remedies were applied simultaneously in a combination therapy.

This study was performed at the Institute for Pharmacology and Toxicology (Pomeranian Medical Academy) in Szczecin, Poland. The director of this study was Professor Dr. med. Jerzy Wojcicki, Head of the Department for Clinical Pharmacology. Dr. med. Lidia Szyroki (Director of the Dermatological Department) and three specialists carried out the study. The study had been approved beforehand by the Ethics Commission of the hospital. Likewise, the patients had been instructed by the examiners regarding the nature, significance, and effect of their participation, and they gave their agreement to participate.

Demographic Data an the Examination

In total, 30 male patients suffering from *Ulcus cruris* of various stages had been admitted to the study. They were treated exclusively with the above SANUM preparations, the contents and effective substances whereof are known to consist of low growth-forms of *Mucor racemosus*. The average age of the patients was 58 years (the youngest patient was 37 years old; the oldest patient was 83 years

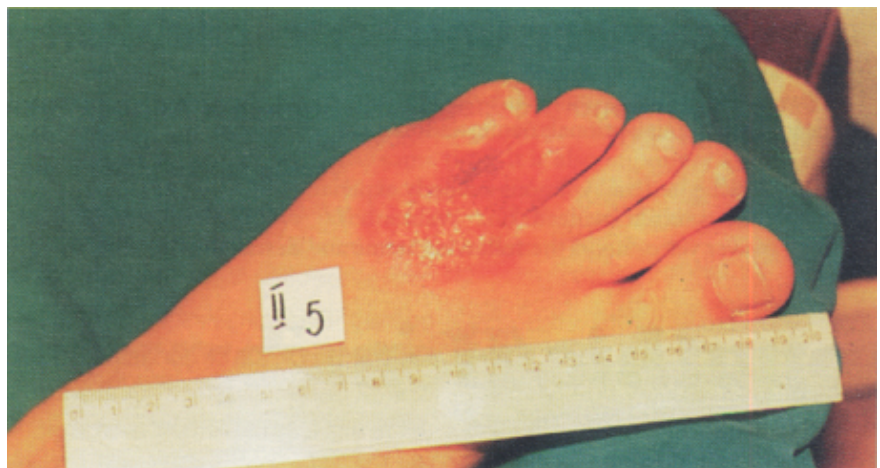old). The average body weight of the patients was 78 kg (minimum 68 kg, maximum 88 kg), with an average body size of 172 cm (minimum 164 cm, maximum 179 cm). In most cases, the *Ulcus cruris* had its pathogenesis in a thrombophlebitis or in varicose veins (*Ulcus varicosum*).

Tests and Treatments According to Their Type and Duration

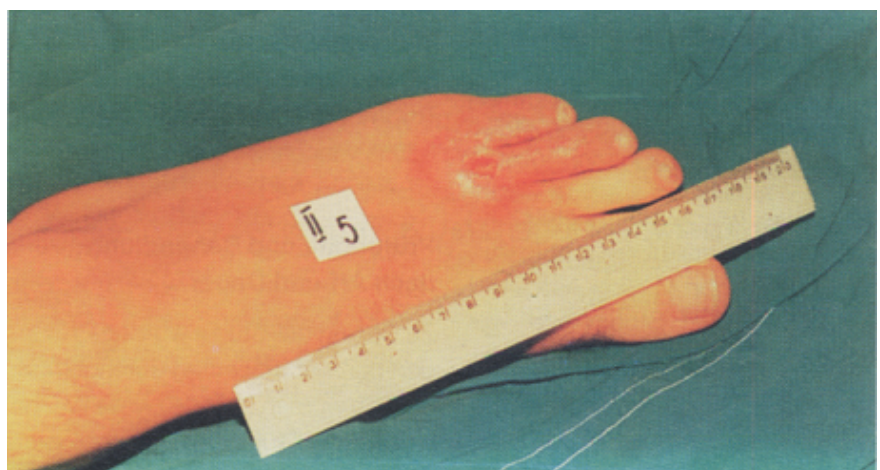
At the beginning of the study, all patients underwent tests. Thereafter, tests were performed every other week. These tests comprised: medical routine examinations, hematological exams, urine analysis, examination of the spread and

depth of lesions, examination of the condition in which the margin of the ulcer is, along with its surrounding tissue, and comparison of the girth of the extremities. Questioning the patients concerning subjective symptoms (pains, pruritis, skin tension, burning sensation) was also part of these examinations.

The study was characterized by “prospective, without comparisons, controlled, and monocentric.” Twice a week (on Tuesdays and Fridays), the patients received an injection of 1 ml ampule of MUCOKEHL 5X i.m.. MUCOKEHL 3X ointment was applied twice daily over the entire surface of the ulceration. The length of the



Picture 1: *Ulcus cruris* ulceration before treatment



Picture 2: *Ulcus cruris* ulceration toward end of treatment

treatment was eight weeks, on the average.

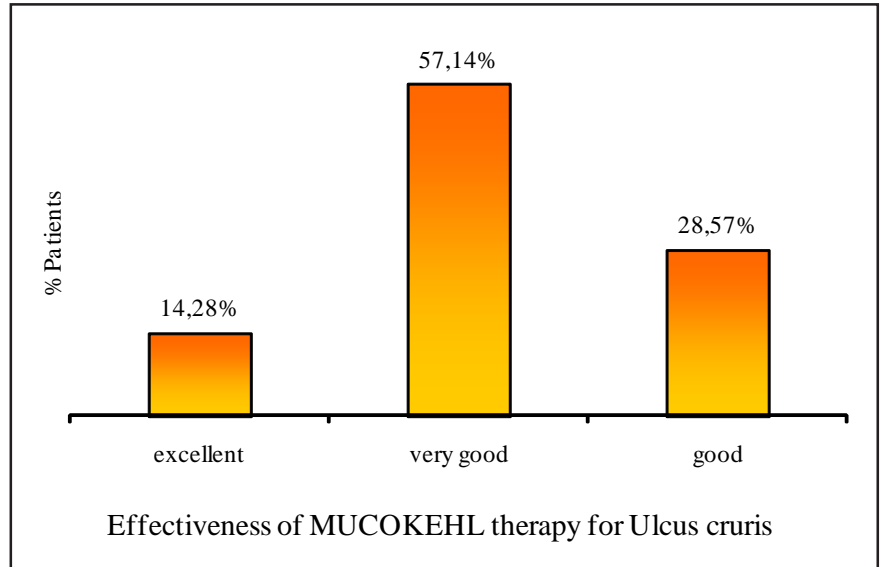
The Results of the Clinical Examinations

Before the treatment, every ulceration was covered with fibrinous pussy coverings or necrotic crusts. Several ulcerations were painful and peripherally strongly inflamed. Already after 5-10 days of the combination treatment with the above preparations, a reduction of the painful symptoms could be noted. There was also a reduction of erythema and secretion indicating the effectiveness of these preparations. The change of bandages occurred with considerably less pain. Moreover, there was a distinct tendency toward the formation of granulations tissue. After 14-28 days of treatment, there was already the beginning of epithelization noticeable.

Concerning the compatibility of the applied SANUM preparations, there was no undesirable systemic side-effect observable in any of the treated patients. The local tolerance also was evaluated as good. The i.m. injections with MUCOKEHL 5X were not felt to be painful, and they caused no inflammations whatever at the point of application. In only one patient was there a temporary erythema at the start of treatment with MUCOKEHL 3X ointment, which disappeared as the therapy progressed.

Evaluation and Discussion of Results

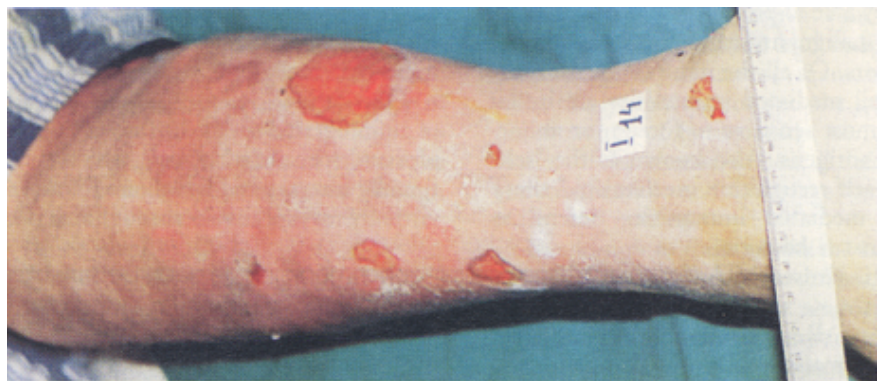The effectiveness of the preparations was evaluated according to the following 5-step scale: "total healing", "excellent", "very good", "good", and "no improvement".



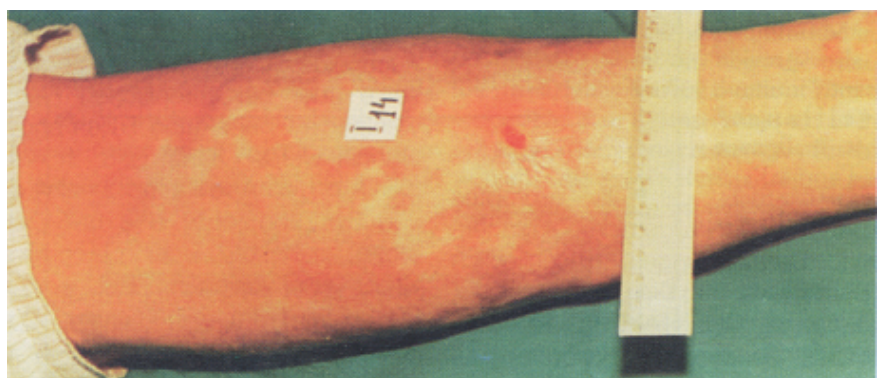Picture 3

Both the objective and subjective symptoms were the basis for the evaluations. In result, the following evaluations of the effectiveness with the patients were determined (see also Picture 3):

- in 14.28% the effect was „excellent“ (see Pictures 1 and 2);
- in 57.14% the effect was „very good“;
- in 28.5% the effect was „good“.



Picture 4: Burn injury before treatment



Picture 5: Burn injury toward end of treatment



This means that in appr. 71% of the patients, there was noted an excellent or very good therapeutical effect of the SANUM preparations. In no case was there noticed a change to the worse or an absence of changes in the ulceration.

Concerning compatibility, neither any systemic nor local signs of incompatibility could be observed for both forms of application. Thus, the cutaneous ointment application, likewise, showed a good compatibility. The submitted results of the study prove that the applied

combinations therapy for *Ulcus cruris* deeply and permanently promotes wound-healing, without any relevant side-effects. In view of the relatively small number of patients examined, it appears appropriate to undertake a larger-scale study for additional confirmation.

Apart from the reported study, during its course there were two patients with severe burns treated with MUCOKEHL 5X injections and MUCOKEHL 3X ointment, according to the identical scheme.

As confirmed by Pictures 4 and 5, here too, a definitely good healing was achieved with these preparations.

First published in the German language in the SANUM-Post magazine (19/1992)

© Copyright 1992 by Semmelweis-Institut GmbH, 27318 Hoya (Weser), Germany

All Rights Reserved